



# Decongestive diuresis using combination intravenous loop diuretics plus chlorothiazide in type 1 acute cardiorenal syndrome and worsening acute kidney injury; a neglected paradigm in resource-poor settings

Macaulay Amechi Chukwukadibia Onuigbo<sup>1,2\*</sup>

<sup>1</sup>The Robert Larner, M.D. College of Medicine, University of Vermont, Burlington, VT, USA

<sup>2</sup>College of Business, University of Wisconsin MBA Consortium, Eau Claire, WI, USA

## ARTICLE INFO

**Article Type:**  
Case Report

### Article History:

Received: 10 July 2019

Accepted: 25 September 2019

Published online: 13 October 2019

### Keywords:

Acute kidney injury

Congestive renal failure

Loop diuretics

Resource-poor settings

Thiazide diuretics

Type I acute cardiorenal syndrome

## ABSTRACT

Over the last decade or more, there has grown a body of evidence demonstrating that renal dysfunction in heart failure is a combination of forward failure from reduced cardiac output and therefore reduced glomerular filtration rate, as well as “congestive renal failure” secondary to renal venous hypertension. We had demonstrated the efficacy of combination intravenous loop diuretics used concurrently with intravenous chlorothiazide to achieve significant renal salvage in such patients at the Mayo Clinic Health System in Northwestern Wisconsin. We describe a similar recent experience with three consecutive elderly patients at the University of Vermont Medical Center, Burlington, VT, USA. We posit that this paradigm of care is underutilized. We argue that aggressive decongestive therapy with combination intravenous loop and thiazide diuretics is a neglected and underutilized mechanism and must be utilized more frequently in the treatment of worsening renal failure with type 1 cardiorenal syndrome. This imperative is even most compelling in resource-poor settings where mechanical ultrafiltration with dialysis or similar machines is not available or simply not affordable. Moreover, we had also demonstrated that accelerated rising Pro B natriuretic peptide (Pro-BNP) in such patients portends a good prognosticator for renal salvage. We present here three consecutive elderly patients recently so managed successfully at the University of Vermont Medical Center in Burlington, VT, USA.

### Implication for health policy/practice/research/medical education:

Accruing evidence has shown that renal dysfunction in heart failure is a combination of forward failure from reduced cardiac output and therefore reduced glomerular filtration rate, as well as “congestive renal failure” secondary to renal venous hypertension. Thus, aggressive decongestive therapy with combination loop and thiazide diuretics must be utilized more frequently in managing worsening renal failure with type 1 cardiorenal syndrome. This imperative is even most compelling in resource-poor settings where mechanical ultrafiltration with dialysis machines is not available or simply not affordable, in a bid to alleviate renal venous congestion and therefore improve kidney function.

*Please cite this paper as:* Onuigbo MAC. Decongestive diuresis using combination intravenous loop diuretics plus chlorothiazide in type 1 acute cardiorenal syndrome and worsening acute kidney injury; a neglected paradigm in resource-poor settings. J Nephroarmacol. 2020;9(2):e13. DOI: 10.15171/npj.2020.13.

## Introduction

Evidence is accruing to prove that renal dysfunction in heart failure is a combination of forward failure from reduced cardiac output and therefore reduced glomerular filtration rate, as well as “congestive renal failure” secondary to renal venous hypertension; the so-called backward failure (1-8). Therefore, aggressive decongestive therapies using combination loop and thiazide diuretics must be utilized more frequently in the treatment of

worsening renal failure with type 1 cardiorenal syndrome (9,10). This is even most imperative in resource-poor settings where mechanical ultrafiltration with dialysis machines is not available or simply not affordable, in a bid to alleviate renal venous congestion and therefore improve kidney function (8,10). Moreover, we had demonstrated in 2017 that accelerated rising Pro B natriuretic peptide (Pro-BNP) levels in such patients portends a good prognosticator for renal salvage (10). We present here

\*Corresponding author: Macaulay Amechi Chukwukadibia Onuigbo, Email: macaulay.onuigbo@uvmhealth.org

a case series of three consecutive elderly patients seen and managed recently over a one-month period in the Summer of 2019, in Burlington, VT, USA.

## Case Presentations

### Patient A

A 78-year male, an ex-smoker, with extensive past medical history including chronic myeloid leukemia on chronic imatinib, 300 mg daily for immunosuppression, heart failure with preserved ejection fraction (EF ; 60-65%), worsening chronic kidney disease (CKD stage IV-V), chronic normocytic anemia (requiring packed red cells transfusion in the past), type II diabetes mellitus, hypertension, obesity, hyperlipidemia, coronary artery disease s/p coronary artery bypass graft procedure in 1999, cerebrovascular disease s/p right carotid endarterectomy, and abdominal aortic aneurysm, was admitted in the Summer of 2019 with several weeks of progressively worsening shortness of breath. He also experienced worsening fatigue, lightheadedness, and leg swelling. In the last few days, the dyspnea had progressed to be present at rest. He had no chest pain but had a chronic cough productive of frothy sputum. He had experienced and recovered from several episodes of acute kidney injury in the past. His outpatient medications were torsemide 60mg twice daily, metolazone 2.5 mg daily, ipratropium inhaler twice daily, potassium chloride, 40 mEq three times daily, metoprolol XL 50 mg daily and oral glipizide XL 5 mg daily.

Temperature was 97.7°F, heart rate ranged from 51 BPM-82 BPM, respiratory rate was 17/min, blood pressure was 148/69 mm Hg and pulse oximetry was 98 % on room air. He weighed 77.1 kg, was 67 inches tall with a body mass index (BMI) of 26.23 kg/m<sup>2</sup>. He was pale, jugular venous pressure was elevated to angle of the jaw, with 2+ pitting edema bilaterally present up to the knees. He had reduced breath sounds in both lung bases with diffuse bilateral inspiratory crackles heard posteriorly in the lower half of the chest. The abdomen was obese, full to distended, with

significant ascites present.

Pertinent admission laboratory values were hemoglobin 6.5 g/dL, WBC 3.1 k/mm<sup>3</sup>, platelet count k/mm<sup>3</sup>, Na 130 mmol/L, potassium 2.7 mmol/L, bicarbonate 27 mmol/L, chloride 92 mmol/L, calcium 8.3 mg/dL, magnesium 2.1 mg/dL, creatinine 3.49 mg/dL, BUN 85 mg/dL and troponin I was 0.077 ng/mL (<0.034). Pro-BNP level was 9,470 pg/mL (<300). A chest radiograph revealed a previously documented left pleural effusion, cardiomegaly, no overt pulmonary vascular congestion, and mild regions of atelectasis in the lower lungs.

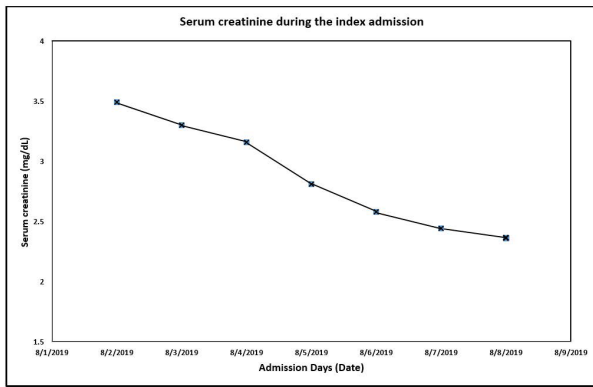
Metoprolol was discontinued because of bradycardia in the 40s. He was transfused two units of packed red cells. Intravenous furosemide 60 mg was given once, followed by intravenous chlorothiazide 500 mg given once with some good diuretic response. Following nephrology consultation, according to “decongestive diuresis” protocol developed earlier at the Mayo Clinic Health System in Northwestern Wisconsin, the concurrent administration of IV furosemide 80 mg every 8 hours sequentially followed by IV chlorothiazide 500 mg every 8 hours administered about half an hour after the IV furosemide was recommended with close monitoring of electrolytes including sodium, potassium, calcium, magnesium and phosphorus. He responded briskly to the combination IV diuretic regimen (Table 1).

Within three days, he was much improved, no longer dyspneic with activity, had lost over 10 lb in weight and the leg swelling had resolved, while the abdominal girth had significantly reduced. Simultaneously, his serum creatinine improved (Table 1, Figure 1). The IV combination diuretics were deescalated to every 12 hours on day 3 and he was switched to oral metolazone 5mg daily plus torsemide 60mg twice daily on hospital day 4 while maintaining fluid restriction of 1500 cc/day. He was counselled on salt restriction, fluid restriction and daily weights on discharge with close follow up with his primary care provider, cardiology and nephrology. Serum creatinine on discharge was 2.36 mg/dL, down from 3.49 mg/dL on admission (Figure 1).

**Table 1.** The presentation and hospital course of the three patients A, B and C

Case	Age (y)	Sex	Hx of CAD	Hx of CHF	LVEF (%)	Pulm HTN	Admission Pro BNP (<300 pg/mL)	Presenting symptom	Admission SCr (mg/dL)	Discharge SCr (mg/dL)	Loop diuretic used (dose)	Thiazide diuretic used (dose)	Maximum 24 h urine (L)	Weight loss (kg)	No. of hospital days
A	78	M	+	+	65	-	9470	Dyspnea	3.49	2.36	IV Furosemide 80 mg q 8 h	IV Thiazide 500 mg Q 12 h	4.6	7.0	6
B	67	M	+	-	65	-	7290	Dyspnea	3.45	2.96	IV Furosemide 120 mg daily	IV Thiazide 500 mg daily	4.3	6.6	3
C	84	M	+	+	45	+	58 000	Dyspnea	3.14	2.21	IV Furosemide 40-120 mg daily	IV Thiazide 250 mg ONCE	2.1	4.0	7

Abbreviations: SCr, serum creatinine; Pro-BNP, Pro B natriuretic peptide; HTN, hypertension; CAD, coronary artery disease; CHF, chronic heart failure (CHF).



**Figure 1.** Serum creatinine trajectory for patient A during the 7-day hospitalization.

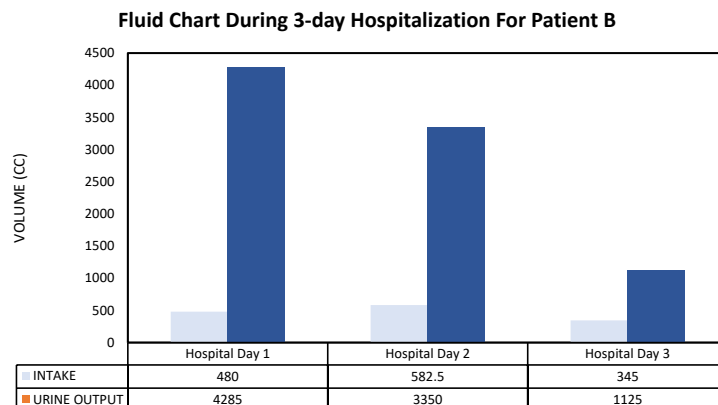
### Patient B

A 67-year old male with a past medical history CKD stage IV, with baseline creatinine in the previous year of 2.4-2.6 mg/dL, previous exacerbations of acute kidney injury on CKD, obesity, longstanding and often uncontrolled type II diabetes mellitus, current HgA1c of 8%, history of multiple sequential amputation procedures in both lower extremities, two prior heart attacks, depression, left popliteal bypass procedure, and right hip fracture two months earlier had presented to the emergency department with worsening leg swelling and exertional dyspnea despite a doubling of the dose of one of his diuretics. He also experienced intermittent nausea with post-prandial vomiting. He had a weight gain of 11 kg and now weighed 88.5 kg, despite continuing oral diuretics, “no salt diet” and supposedly a 1.5 L/day fluid restriction. He had urinary frequency and had consistently expressed disinterest in renal replacement therapy. Outpatient medications were metolazone 5 mg daily and torsemide, 60 mg twice daily, a doubling of the dose from the previous week.

In the emergency department, temperature was 98.4 °F, pulse was 61 beats per minute (BPM), respiratory rate

20/min, blood pressure was 160/80 mm Hg and pulse oximetry was 94 % on room air. He weighed 88.5 kg, was 67 inches tall with a BMI of 30.6 kg/m<sup>2</sup>. He appeared older than stated age, was pale, alert, oriented and non-focal. He had gross bilateral lower extremity edema up to the knees, healing ulcers in both mid shins with some surrounding erythema and a left foot flap site wound. Pertinent admission laboratory values were hemoglobin 7.4 g/dL, WBC 6.7 k/mm<sup>3</sup>, platelet count 99 k/mm<sup>3</sup>, Na 127 mmol/L, potassium 4.4 mmol/L, bicarbonate 16 mmol/L, chloride 97 mmol/L, calcium 7.9 mg/dL, creatinine 3.32 mg/dL, BUN 102 mg/dL and troponin I was <0.034 ng/mL. Pro BNP level which was 2230 pg/mL (<300) in September 2018 was now higher at 7290 pg/mL. Urinalysis showed 2+ Blood, 2+ Protein, with 11-50 RBC/HPF, 0-3 WBC/HPF and no bacteria. Chest radiograph revealed cardiomegaly, hypo-inflation of both lungs, mild pulmonary vascular congestion and small bilateral pleural effusions. Renal ultrasound showed a 12 cm right kidney, a 9.4 cm left kidney, normal cortical echogenicity and thickness and no hydronephrosis or renal calculi. The urinary bladder was decompressed by a Foley catheter. A recent echocardiogram showed preserved left ventricular ejection fraction of 60%-65%, mild-moderate tricuspid regurgitation, and mildly dilated right ventricle with elevated pulmonary artery pressures of 55 mm Hg to 60 mm Hg.

On admission, he received IV Furosemide 120 mg daily in combination with IV hydrochlorothiazide, 500 mg daily with excellent diuresis (Figure 2). By hospital day 3, he was improved. The leg swelling and dyspnea had improved with significant weight loss (Table 1). Serum creatinine decreased from 3.45 mg/dL to 2.96 mg/dL on hospital day 3. He was discharged home after three days on oral torsemide 60 mg two times a day with metolazone 5 mg daily for diuretics, no added salt, to weigh himself daily, fluid restriction of 1500 cc/day and follow up with his primary provider.



**Figure 2.** Intake-output chart for patient B during the 3-day hospitalization.

### Patient C

An 84-year old male with history of ischemic heart disease, an ex-smoker, previous coronary artery bypass grafting, chronic diastolic heart failure with secondary pulmonary hypertension on 2 LPM supplemental oxygen, sleep apnea, type II diabetes mellitus on insulin, questionable liver cirrhosis and CKD was transferred by Emergency Medical Services to our emergency department (ED) with worsening dyspnea on exertion in the summer of 2019. A prior echocardiogram had demonstrated reduced left ventricular systolic function with an ejection fraction of 40%-45% and diffuse hypokinesis with regional variations. Pulmonary systolic pressure was high at 75 mm Hg with severely reduced right ventricular systolic function. The progressive worsening dyspnea on exertion had gone on for about 2 weeks and acutely worsened in the past 2 days. The son reported some fever. He had cough with increased sputum production, but no urinary symptoms, no abdominal pain, nausea or vomiting. Appetite was poor. He experienced orthopnea and had increasing lower extremity swelling with a daily weight gain of nearly 1 kg for the previous one week. Outpatient medications were torsemide 40 mg daily and metolazone 5 mg daily. It appeared that for some unclear reasons, possibly due to confusion, the patient may have discontinued his diuretics for some days before the presentation to the emergency department. Upon arrival in the emergency department, the patient's oxygen saturation was in the mid 80's. His oxygen saturation improved to 96% after a Bi-pap mask with high-flow oxygen was applied to his face.

Admission vital signs showed blood pressure as low as 69/60 mm Hg, heart rate of 92-106 bpm, temperature 97.9 0F, and a respiratory rate of up to 40/minute. He was tachypneic with increased work of breathing, tachycardia, bilateral lower edema, 2+, up to both knees, a Foley catheter to a bag, and coarse inspiratory crackles in both lung bases. Pertinent laboratory values were hemoglobin 8.7 gm/dL, WBC 14.01 k/mm<sup>3</sup>, platelet count 98 k/mm<sup>3</sup>, Na 136 mmol/L, potassium 4.1 mmol/L, bicarbonate 24 mmol/L, chloride 97 mmol/L, calcium 7.9 mg/dL, magnesium 1.8 mg/dL, creatinine 3.14 mg/dL, BUN 75 mg/dL and troponin I was 0.288 (<0.034 ng/mL). Notably, serum creatinine was 2.03 mg/dL six weeks earlier. Pro BNP level was 58 000 pg/mL (<300) on admission. Chest radiograph demonstrated cardiomegaly, pulmonary vascular congestion and multifocal airspace opacities in the right upper lobe and in the retro-cardiac areas of the left lung. Urine *Legionella pneumophila* serogroup 1, urine methicillin-resistant *Staphylococcus aureus*, urine *Streptococcus pneumoniae* antigen, and stool clostridium difficile PCR tests were all negative. Nevertheless, from paired blood cultures, *Streptococcus pneumoniae* was detected in the aerobic bottle at 13 hours, and was subsequently detected in both bottles at 15 hours. Repeated paired blood cultures on hospital day 1 and day 8 remained negative. An EKG showed atrial fibrillation with

rapid ventricular response, right axis deviation, and right bundle branch block without acute ischemia. A bedside cardiac ultrasound revealed reduced ejection fraction, plethoric inferior vena cava but no pericardial effusion.

Admission diagnoses included acute on chronic hypoxic respiratory failure from multifocal pneumonia and pulmonary edema, together with a suspicion for sepsis and intravenous ceftriaxone and azithromycin were initiated after blood cultures were drawn. Norepinephrine was started for hypotension. For volume overload and heart failure, he received IV furosemide 80 mg daily with additional doses as needed. Overnight, he improved and was weaned off norepinephrine and the Bi-pap machine. On hospital day 2, IV chlorothiazide, 250 mg infusion, was administered once. He continued to achieve significant diuresis (Table 1). He completed five days of azithromycin and ceftriaxone, and was subsequently to complete five more days of oral Cefpodoxime, 400 mg daily. On hospital day 7, he was discharged feeling great and improved on three more days of oral cefpodoxime, 400 mg daily, furosemide 40 mg twice daily, metolazone 2.5 mg daily, fluid restriction of 1.5 L/day, daily weights and follow up with primary care provider within the week. Serum creatinine had improved and was 2.21 mg/dL.

Unfortunately, he was readmitted 2 days later with altered mental status, diagnoses of hospital-acquired delirium and encephalopathy and myoclonus, new leukocytosis (15.44 K/cmm), stable chest radiograph and stable kidney function. He was empirically started on intravenous ampicillin/sulbactam. Diuresis was held in the setting of decreased intake and absence of signs of volume overload. Urine and blood cultures revealed no new growth. He did not get better, remained somnolent and Palliative Care was consulted. He was then discharged to Hospice care and he soon passed away.

### Discussion

Our patients all presented with progressive dyspnea, fluid retention and worsening renal failure despite continued administration of combination oral loop and thiazide diuretics as outpatients (10). However, they all showed prompt and sustained diuresis with combination intravenous loop diuretics and intravenous chlorothiazide administered concurrently, despite significant cardio-renal impairment (10). We were able to achieve excellent diuretic responses in such patients with type 1 acute cardio-renal syndrome despite the presence of significant renal failure (Table 1). Indeed, in 2017, at the Mayo Clinic Health System in Northwestern Wisconsin, we achieved nearly 10 L of urine output in a space of 24 hours with such approach (10). This degree of "renal ultrafiltration" thus far exceeded the mechanical ultrafiltration targets reported in the cardio-renal literature using mechanical dialysis machines (9,10). These accomplishments with pharmacologic decongestive diuresis with intravenous loop diuretic and intravenous chlorothiazide administered



concurrently and sequentially represent a testament to the potent synergy that can be achieved using these two classes of diuretics most effectively despite the presence of oral diuretic resistance associated with cardiorenal syndrome (10,11).

One impressive outcome of successful pharmacologic decongestive diuresis in these patients is the return of sensitivity to oral diuretics in these patients (10). The prevailing hypotheses to explain this resolution, albeit temporarily of oral diuretic resistance, include the improved renal function from reduction of renal venous hypertension as well as the resolution of intestinal edema from the same systemic venous hypertension following the decongestive diuresis (12,13). Indeed, a recent review concluded that abdominal congestion (i.e., splanchnic venous and interstitial congestion) manifests in a substantial number of patients with advanced congestive heart failure, even though this is poorly defined (12). It went on to note that compromised capacitance function of the splanchnic vasculature and deficient abdominal lymph flow resulting in interstitial edema might both be implicated in the occurrence of increased cardiac filling pressures and renal dysfunction (12). Indeed, increased intra-abdominal pressure, as an extreme marker of abdominal congestion, is correlated with renal dysfunction in advanced congestive heart failure (12). Furthermore, a 2018 single-center, prospective, observational study of 224 hospitalized Japanese patients after acute decompensated heart failure demonstrated that increased portal congestion and intestinal edema were associated with severe heart failure symptoms and poor outcomes in hospitalized heart failure patients, in addition to being associated with impaired right-sided cardiac function (13).

Finally, the post-discharge management of such patients after a successful stint in the hospital calls for further review. There is a very high rate of recrudescence of similar presentation requiring repeated re-admissions. There is therefore this grossly unmet need of very close monitoring of these patients, post-discharge with daily weights, strict fluid restriction and no added salt diets. Any unexpected weight gains must trigger immediate pre-emptive actions on the part of the providers. The establishment of a monitoring system, with weekly phone calls to the patients, and a review of daily weights will enable the diagnosis of early failing outpatient diuresis and a consideration for either increased dose of outpatient oral diuretics or even a pre-emptive emergency room visit and the use of IV diuretics to prevent a full hospital re-admission. On the other hand, the setting up of pre-determined brief overnight IV combination diuresis protocols may obviate the need for recurrent costly full-blown re-admissions.

We argue that the effective and efficacious adoption of this maneuver be more aggressively enabled especially

in resource-poor settings around the world, in a bid to alleviate renal venous congestion and therefore sustainably improve kidney function.

### Conclusion

We have demonstrated in this case series the efficacy of combination sequential intravenous loop and thiazide diuretics in the establishment of decongestive diuresis and the successful management of symptomatic acute type 1 cardiorenal syndrome. There is often rapid therapeutic response with resolution of symptoms coupled with improvement in kidney function. Furthermore, the apparent diuretic resistance to oral diuretics is reset and these patients frequently reacquire new sensitivity to oral diuretics, most likely due to improved kidney function as well as concurrently resolved gut edema and therefore enhanced oral bioavailability of the oral diuretics. We call for a more aggressive utilization of this modality of treatment especially in resource-poor settings where mechanical ultrafiltration with dialysis machines is either not available or prohibitively too expensive and therefore unaffordable. Finally, we call for improved post-discharge care and follow up to mitigate against recurrent readmissions among these patients. In this manner, we would have succeeded in improving morbidity and mortality outcomes in this patient group.

### Author's contribution

Conception of the project: MACO. Data acquisition: MACO. Literature review: MACO. Drafting the manuscript: MACO. Final approval of the article: MACO

### Conflicts of interest

The author declares no conflicts of interest.

### Ethical considerations

Ethical issues (including plagiarism, data fabrication, double publication) have been completely observed by the author. The patients have been provided their consent to publish this paper.

### Funding/Support

None.

### References

1. Ross EA. Congestive renal failure: The pathophysiology and treatment of renal venous hypertension. *J Card Fail.* 2012;18:930–938. doi: 10.1016/j.cardfail.2012.10.010.
2. Heywood JT, Fonarow GC, Costanzo MR, Mathur VS, Wigneswaran JR, Wynne J. ADHERE Scientific Advisory Committee and Investigators. High prevalence of renal dysfunction and its impact on outcome in 118,465 patients hospitalized with acute decompensated heart failure: A report from the ADHERE database. *J Card Fail.* 2007;13:422-30. doi: 10.1016/j.cardfail.2007.03.011.
3. Nohria A, Hasselblad V, Stebbins A, Pauly DF, Fonarow

- GC, Shah M, et al. Cardiorenal interactions: Insights from the ESCAPE trial. *J Am Coll Cardiol*. 2008;51:1268-74. doi: 10.1016/j.jacc.2007.08.072.
4. Damman K, van Deursen VM, Navis G, Voors AA, van Veldhuisen DJ, Hillege HL. Increased central venous pressure is associated with impaired renal function and mortality in a broad spectrum of patients with cardiovascular disease. *J Am Coll Cardiol*. 2009;53:582-588. doi: 10.1016/j.jacc.2008.08.080.
  5. Damman K, Voors AA, Hillege HL, Navis G, Lechat P, van Veldhuisen DJ, et al. CIBIS-2 Investigators and Committees. Congestion in chronic systolic heart failure is related to renal dysfunction and increased mortality. *Eur J Heart Fail*. 2010;12:974-982. doi: 10.1093/eurjhf/hfq118.
  6. Guglin M, Rivero A, Matar F, Garcia M. Renal dysfunction in heart failure is due to congestion but not low output. *Clin Cardiol*. 2011;34:113-36. doi: 10.1002/clc.20831.
  7. Maeder MT, Holst DP, Kaye DM. Tricuspid regurgitation contributes to renal dysfunction in patients with heart failure. *J Card Fail*. 2008;14:824-30. doi: 10.1016/j.cardfail.2008.07.236.
  8. Damman K, Navis G, Smilde TD, Voors AA, van der Bij W, van Veldhuisen DJ, et al. Decreased cardiac output, venous congestion and the association with renal impairment in patients with cardiac dysfunction. *Eur J Heart Fail*. 2007;9:872-8.
  9. Rossi GP, Calò LA, Maiolino G, Zoccali C. Ultrafiltration for the treatment of congestion: A window into the lung for a better caress to the heart. *Nephrol Dial Transplant*. 2014; 29:1335-41. doi: 10.1093/ndt/gft371.
  10. Onuigbo MAC, Agbasi N, Sengodan M, Rosario KF. Acute Kidney injury in heart failure revisited-the ameliorating impact of “decongestive diuresis” on renal dysfunction in type 1 acute cardiorenal syndrome: accelerated rising pro b natriuretic peptide is a predictor of good renal prognosis. *J Clin Med*. 2017;6:82. doi: 10.3390/jcm6090082.
  11. Verbrugge FH, Mullens W, Tang WH. Management of cardio-renal syndrome and diuretic resistance. *Curr Treat Opt Cardiovasc Med*. 2016;18:11. doi: 10.1007/s11936-015-0436-4.
  12. Verbrugge FH, Dupont M, Steels P, Grieten L, Malbrain M, Tang WH, et al. Abdominal contributions to cardiorenal dysfunction in congestive heart failure. *J Am Coll Cardiol*. 2013;62:485-95. doi: 10.1016/j.jacc.2013.04.070.
  13. Ikeda Y, Ishii S, Yazaki M, Fujita T, Iida Y, Kaida T, et al. Portal congestion and intestinal edema in hospitalized patients with heart failure. *Heart Vessels*. 2018;33:740-751. doi: 10.1007/s00380-018-1117-5.

**Copyright** © 2020 The Author(s); Published by Society of Diabetic Nephropathy Prevention. This is an open-access article distributed under the terms of the Creative Commons Attribution License (<http://creativecommons.org/licenses/by/4.0>), which permits unrestricted use, distribution, and reproduction in any medium, provided the original work is properly cited.