



# COVID-19-associated thrombotic thrombocytopenic purpura (TTP); a case report

Ali Hajigholami<sup>1\*</sup>, Hourieh Ansari<sup>2</sup>, Sakineh Ansari<sup>1</sup>, Shakiba Hassanzadeh<sup>3</sup>

<sup>1</sup>Department of Internal Medicine, Isfahan University of Medical Sciences, Isfahan, Iran

<sup>2</sup>Department of Community and Preventive Medicine, Isfahan University of Medical Sciences, Isfahan, Iran

<sup>3</sup>Nickan Research Institute, Isfahan, Iran

## ARTICLE INFO

**Article Type:**  
Case Report

**Article History:**

Received: 17 October 2021

Accepted: 1 December 2021

Published online: 18 December 2021

**Keywords:**

COVID-19, Thrombotic thrombocytopenic purpura, Infection, Autoimmune

## ABSTRACT

The severe acute respiratory syndrome coronavirus 2 (SARS-CoV-2) or coronavirus disease (COVID-19) pandemic is the largest infectious crisis in the present century. It has been reported that COVID-19 infection may trigger autoimmune diseases. Herein, we report a 68-year-old male that was diagnosed with thrombotic thrombocytopenic purpura (TTP) following COVID-19 infection. To our knowledge, this is the fourth case of COVID-19-associated TTP. More attention is required regarding the possibility of developing TTP in COVID-19 patients, especially with the presence of decreased consciousness and low levels of hemoglobin and platelet.

### *Implication for health policy/practice/research/medical education:*

Coronavirus disease-19 (COVID-19) has been reported to trigger autoimmune diseases including thrombotic thrombocytopenic purpura (TTP). Therefore, more attention is recommended towards the possibility of developing TTP in COVID-19 patients.

*Please cite this paper as:* Hajigholami A, Ansari H, Ansari S, Hassanzadeh S. COVID-19-associated thrombotic thrombocytopenic purpura (TTP); a case report. J Nephropharmacol. 2023;12(1):e10454. DOI: 10.34172/npj.2022.10454.

## Introduction

Severe acute respiratory syndrome coronavirus 2 (SARS-CoV-2) or coronavirus disease (COVID-19) was first identified in China in December 2020, and then, was declared as a pandemic. The clinical symptomatic spectrum of COVID-19 infection ranges from mild to severe. Fever, cough, dyspnea, and myalgia are the most common symptoms (1).

It has been reported that COVID-19 can trigger some autoimmune diseases (2,3). Thrombotic thrombocytopenic purpura (TTP) is a rare and life-threatening disorder (4) that is characterized by widespread platelet thrombi in the arterioles and capillaries as well as diffuse endothelial inflammation (5). In addition, viral infections have been associated with thrombotic microangiopathy (6). Fever, thrombocytopenia, microangiopathic hemolytic anemia, neurological symptoms, and renal insufficiency are among the signs of acute TTP (7). Moreover, elevated lactate dehydrogenase, bilirubin, creatinine, and liver

transaminases together with decreased levels of platelet and hemoglobin are the laboratory characteristics of TTP (8).

To our knowledge, three cases of TTP have been reported in COVID-19 patients (9-11). Herein, we report another case of TTP following severe COVID-19 infection. This may help to better understand the association between COVID-19 infection and TTP.

## Case Presentation

A 68-year-old male was referred to and hospitalized at our emergency department. His clinical features did not improve after admission to a healthcare center three days before hospitalization. He had a one-month history of progressive malaise and weakness. His past medical history was insignificant. On admission, he complained of progressive malaise and weakness. The symptoms were progressive and the patient was unable to do his routine activity. Additionally, exertional dyspnea, productive

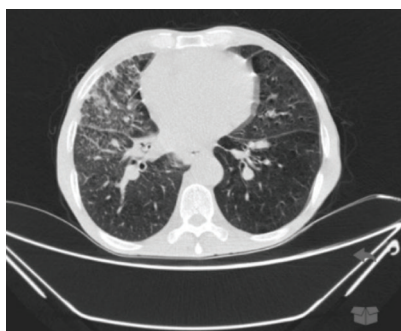\*Corresponding author: Ali Hajigholami, Email: alihajigholami@med.mui.ac.ir

cough, and hemoptysis were present. However, he denied having a fever or headache. On admission, the patient was afebrile but was confused with no orientation to time. He had a blood pressure of 115/80 mm Hg, a heart rate of 68 beats/min, a respiratory rate of 15 times/min, a temperature of 37°C, and O<sub>2</sub> saturation of 90%. On physical examination, there were rales at the bases of both lungs, weak heart sounds without any friction rub, 2+ edema of the lower extremities, normal neurological examination, and no asterixis.

ECG (electrocardiogram) showed low QRS voltage in the limb leads. Brain computed tomography (CT) scan showed generalized atrophy and hydrocephaly without any acute pathological evidence. Furthermore, a high-resolution CT scan of the lungs reported diffuse hyper-aeration of both lungs with interstitial infiltrations in the right middle, right upper, and right lower lobes as well as inter-lobar fissural nodular lesions. These findings were compatible with COVID-19 infection, chronic obstructive pulmonary disease, and interstitial lung disease (Figure 1). Bedside echocardiography reported a left ventricular ejection fraction of 20%, global hypokinesia, normal right ventricle size, severe mitral regurgitation, moderate aortic insufficiency, moderate tricuspid regurgitation, pulmonary artery pressure of 40-45 mm Hg, and no pericardial effusion. The laboratory reports are demonstrated in Table 1.

The patient was transferred to the intensive care unit. He was treated with methylprednisolone, meropenem, and levofloxacin. A peripheral blood smear (PBS) was performed which revealed low platelets with approximately more than 2% schistocytes (Figure 2). The diagnosis of TTP was established based on the presence of hemolytic anemia, thrombocytopenia, high creatinine level, and a confused state.

Urgent right femoral access was placed and therapeutic plasmapheresis was initiated. Six plasmapheresis sessions were administered. His platelet levels decreased at first but increased subsequently (Table 1). Rituximab was prescribed on day eight of hospitalization. Nine days after admission, the patient developed respiratory distress and



**Figure 1.** Chest computed tomography (CT); diffuse hyper-aeration of both lungs with interstitial infiltrations in the right middle, right upper, and right lower lobes as well as inter-lobar fissural nodular lesions.

**Table 1.** The patient's laboratory results

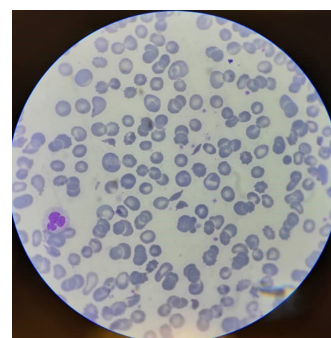
Laboratory parameter	Laboratory result
Blood sugar	168 mg/dL
Alanine transaminase	52 U/L
Aspartate transaminase	60 U/L
Alkaline phosphatase	196 U/L
Bilirubin (Total)	1.75 mg/dL
Bilirubin (Direct)	0.8 mg/dL
Blood urea nitrogen	95 mg/dL
Creatinine	3.5 mg/dL
Na (Sodium)	131 mEq/L
K (Potassium)	3.6 mEq/L
Calcium	8.09 mg/dL
Phosphorus	4.36 mg/dL
Magnesium	2.37 mg/dL
Albumin	2.2 g/dL
White blood cell	15200/μL
Hemoglobin	10.4 g/dL
Platelet	105000/μL
Ferritin	539 ng/L
Fe, Iron	123 μg/L
Total iron-binding capacity	243 μg/L
Retic count	8.1%
Lactic dehydrogenase	984 U/L
Creatine phosphokinase	221 U/L
International normalized ratio	1.4 ratio
Partial thromboplastin time	44 s
Erythrocyte sedimentation rate (1 hour)	4 mm/h
C-reactive protein	49 mg/L
D-dimer	300 ng/mL
Amylase	30 U/L
Lipase	27.2 U/L
RT-PCR for COVID-19	Positive

RT-PCR, reverse transcription-polymerase chain reaction.

cardio-pulmonary arrest. Cardiopulmonary resuscitation (CPR) was immediately initiated but was unsuccessful and the patient expired.

## Discussion

Different hematologic abnormalities have been associated



**Figure 2.** Chest computed tomography (CT); diffuse hyper-aeration of both lungs with interstitial infiltrations in the right middle, right upper, and right lower lobes as well as inter-lobar fissural nodular lesions.

with severe COVID-19 including various types of thromboembolic events, especially in the presence of acute respiratory distress syndrome (12). TTP can result in multi-organ dysfunction or death. In this study, increasing creatinine level, loss of consciousness, decreased hemoglobin level, thrombocytopenia, and positive polymerase chain reaction (PCR) for SARS-CoV2 were observed. Therefore, the patient was diagnosed with TTP following COVID-19 infection.

To our knowledge, there have been three reported cases of COVID-19-associated TTP. Hindilerden et al reported a 74-year-old woman who presented with progressive fatigue and dry cough following a diagnosis of COVID-19. Their patient had lethargy concomitantly with thrombocytopenia and microangiopathic hemolytic anemia associated with positive PBS findings for TTP (10). Similarly, Albiol et al reported the presence of microangiopathic hemolytic anemia, severe thrombocytopenia, low activity (2%) of ADAMTS-13, and the presence of an ADAMTS-13 inhibitor in a 57-year-old woman leading to the diagnosis of TTP. ADAMTS-13 inhibitor is an autoantibody against ADAMTS-13 (11). In addition, Capecchi et al reported a 55-year-old female that was admitted with malaise, chest discomfort, and dyspnea. She had a history of TTP which was induced with bacterial pneumonia 30 years earlier with successful treatment. About one month before admission, she had mild influenza-like symptoms that self-resolved. On admission, her SARS-CoV-2 test was negative. However, her serological test was positive for specific IgG indicating previous COVID-19 infection. The diagnosis of TTP was established with the presence of anemia, increased hemolysis, schistocytes on the PBS, undetectable plasma ADAMTS13 activity, and a high titer of anti-ADAMTS13 inhibitor (9). All of the previous cases were successfully treated and the platelet counts increased to the normal value.

The diagnosis of TTP was established in our case based on the patient's clinical presentation (progressive decrease in the consciousness level) and laboratory data (decreased levels of hemoglobin and platelet and PBS findings). However, despite several plasmapheresis sessions and subsequent rituximab administration, therapy for this patient failed and he expired. His death may be due to the involvement of both lungs, late diagnosis, and severe COVID-19 infection.

## Conclusion

We report a patient diagnosed with COVID-19-associated TTP. We emphasize the importance of early diagnosis of TTP in patients with COVID-19 infection, especially in those who have decreased consciousness and reduced levels of hemoglobin and platelet. Consequently, immediate treatment would be initiated which may be beneficial and increase the patient's survival.

## Authors' contribution

Conceptualization, validation, resources, data curation, visualization, supervision, project administration: AH. Investigation: AH and HA. Writing—original draft preparation: AH, SA and HA. Writing—review and editing: SH.

## Conflicts of interest

The authors declare that they have no competing interests.

## Ethical issues

This manuscript was conducted based on the World Medical Association Declaration of Helsinki. Written informed consent was taken from the patients for its publication. Additionally, ethical issues (including plagiarism, data fabrication, double publication) have been completely observed by the authors.

## Funding/Support

None.

## References

1. Lai CC, Shih TP, Ko WC, Tang HJ, Hsueh PR. Severe acute respiratory syndrome coronavirus 2 (SARS-CoV-2) and coronavirus disease-2019 (COVID-19): The epidemic and the challenges. *Int J Antimicrob Agents*. 2020;55:105924. doi: 10.1016/j.ijantimicag.2020.105924.
2. Abu-Rumeileh S, Abdelhak A, Foschi M, Tumani H, Otto M. Guillain-Barré syndrome spectrum associated with COVID-19: an up-to-date systematic review of 73 cases. *J Neurol*. 2021;268:1133-1170. doi: 10.1007/s00415-020-10124-x.
3. Mateu-Salat M, Urgell E, Chico A. SARS-CoV-2 as a trigger for autoimmune disease: report of two cases of Graves' disease after COVID-19. *J Endocrinol Invest*. 2020;43:1527-8. doi: 10.1007/s40618-020-01366-7.
4. Joly BS, Coppo P, Veyradier A. Thrombotic thrombocytopenic purpura. *Blood*. 2017;129:2836-46. doi: 10.1182/blood-2016-10-709857.
5. Varga Z, Flammer AJ, Steiger P, Haberecker M, Andermatt R, Zinkernagel AS, et al. Endothelial cell infection and endotheliitis in COVID-19. *Lancet*. 2020;395:1417-8. doi: 10.1016/S0140-6736(20)30937-5.
6. Hymes K, Karparkin S. Human immunodeficiency virus infection and thrombotic microangiopathy. *Semin Hematol*. 1997;34:117-25.
7. Scully M, Yarranton H, Liesner R, Cavenagh J, Hunt B, Benjamin S, et al. Regional UK TTP Registry: correlation with laboratory ADAMTS 13 analysis and clinical features. *Br J Haematol*. 2008;142:819-26. doi: 10.1111/j.1365-2141.2008.07276.x.
8. Mancini I, Pontiggia S, Palla R, Artoni A, Valsecchi C, Ferrari B, et al. Clinical and laboratory features of patients with acquired thrombotic thrombocytopenic purpura: fourteen years of the Milan TTP Registry. *Thromb Haemost*. 2019;119:695-704. doi: 10.1055/s-0039-1679907.
9. Capecchi M, Mocellin C, Abbruzzese C, Mancini I, Prati D, Peyvandi F. Dramatic presentation of acquired TTP

- associated with COVID-19. *Haematologica*. 2020;105:e540-1. doi: 10.3324/haematol.2020.262345.
10. Hindilerden F, Yonal-Hindilerden I, Akar E, Kart-Yasar K. Covid-19 associated autoimmune thrombotic thrombocytopenic purpura: Report of a case. *Thrombosis Research*. 2020;195:136-8.
  11. Albiol N, Awol R, Martino R. Autoimmune thrombotic thrombocytopenic purpura (TTP) associated with COVID-19. *Ann Hematol*. 2020;99:1673-4. doi: 10.1007/s00277-020-04097-0.
  12. Helms J, Tacquard C, Severac F, Leonard-Lorant I, Ohana M, Delabranche X, et al. High risk of thrombosis in patients with severe SARS-CoV-2 infection: a multicenter prospective cohort study. *Intensive Care Med*. 2020;46:1089-98. doi: 10.1007/s00134-020-06062-x.

**Copyright** © 2023 The Author(s); Published by Society of Diabetic Nephropathy Prevention. This is an open-access article distributed under the terms of the Creative Commons Attribution License (<http://creativecommons.org/licenses/by/4.0>), which permits unrestricted use, distribution, and reproduction in any medium, provided the original work is properly cited.